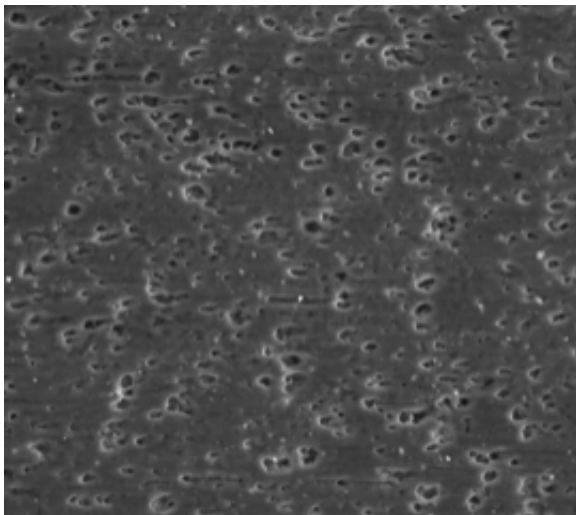





POST OP 4 SURGEON ANECDOTAL SUBMISSION OF CES
HA INTEGRATED CAGES - ALL PATIENTS WITH TLIF PROCEDURES
AND TREATED WITH AUTOGRAFT INSIDE THE CAGE :
6 / 10/ 14 / 24 WEEKS XRAYs AND CT SCANS

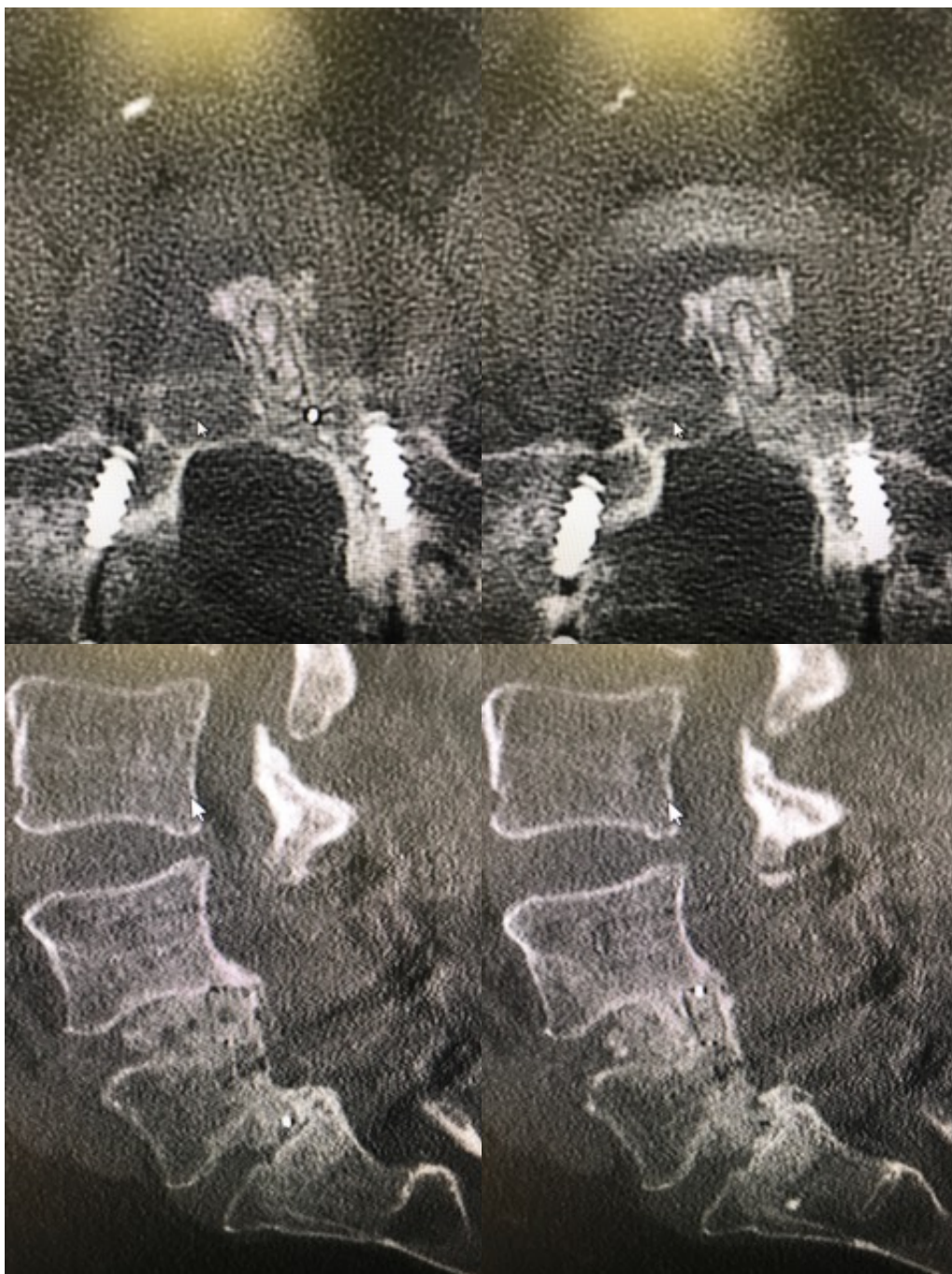


MICROSCOPIC IMAGE OF PEEK

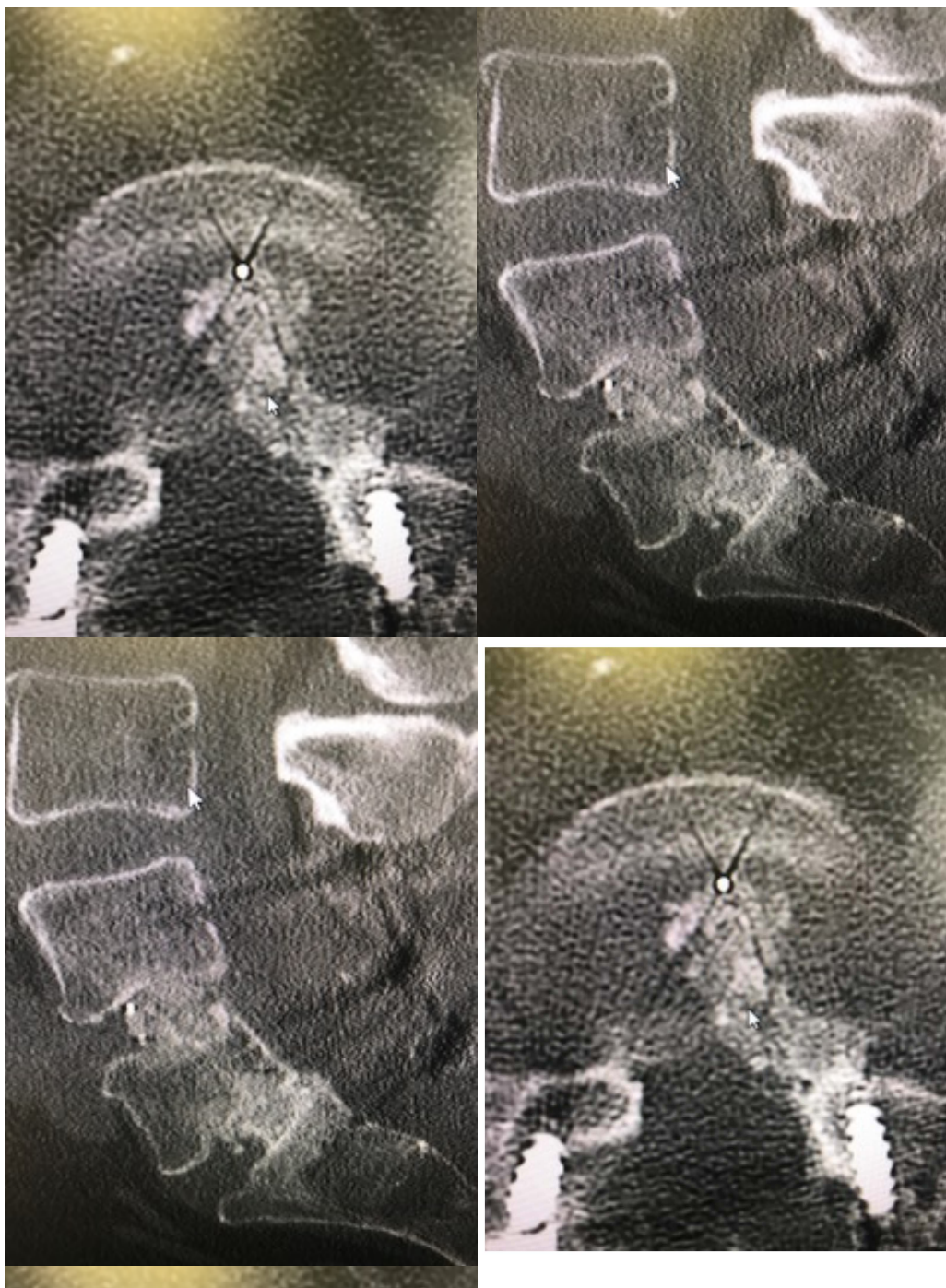


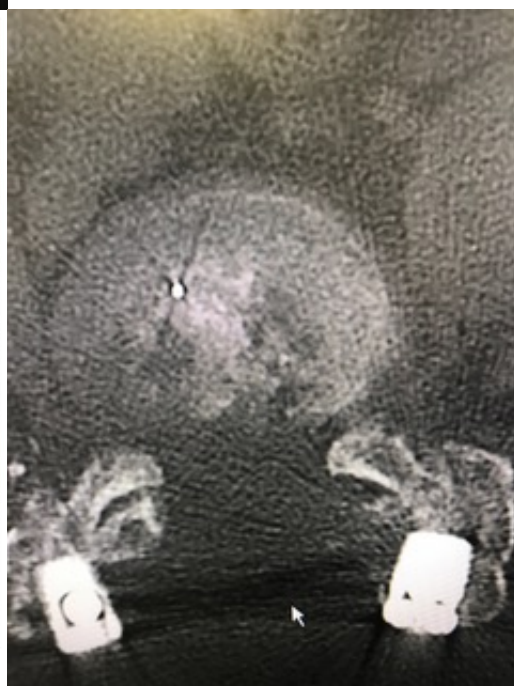
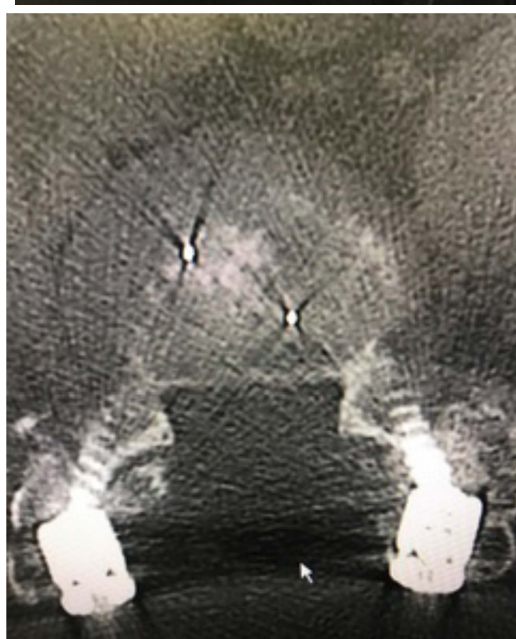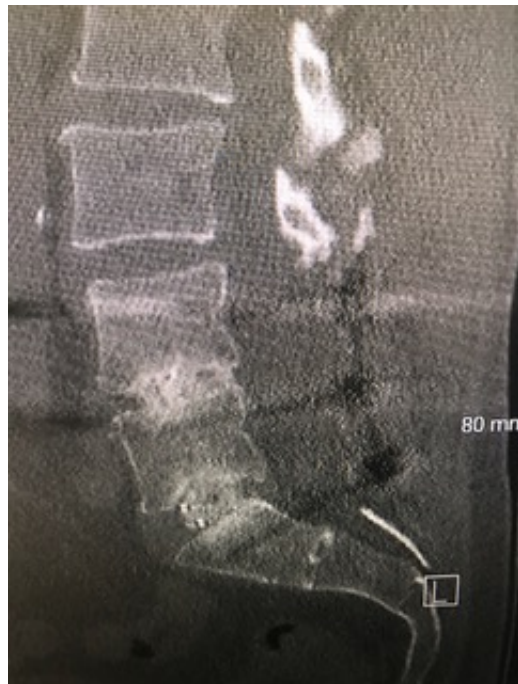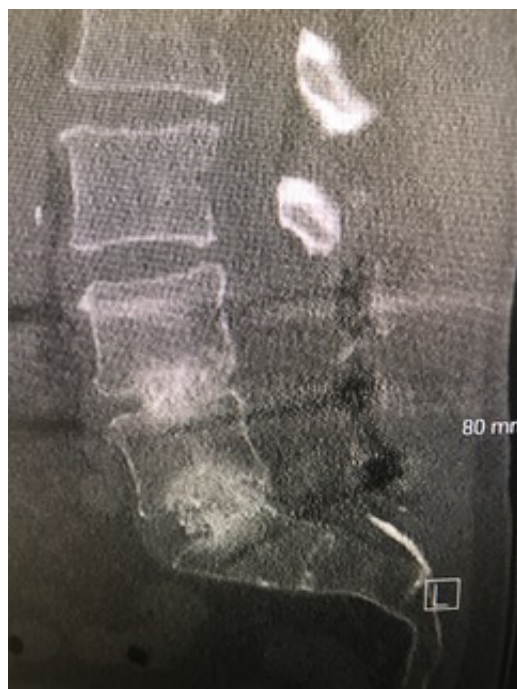MICROSCOPIC IMAGE OF HA INTEGRATED PEEK

PT# 1 - CT Scans - CES HA Enhanced
Cages - 6 WEEKS



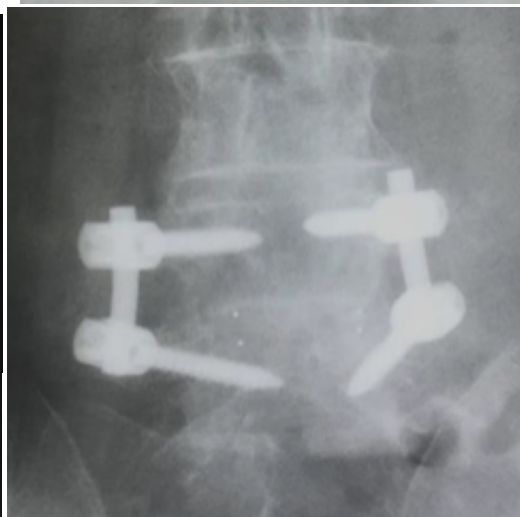
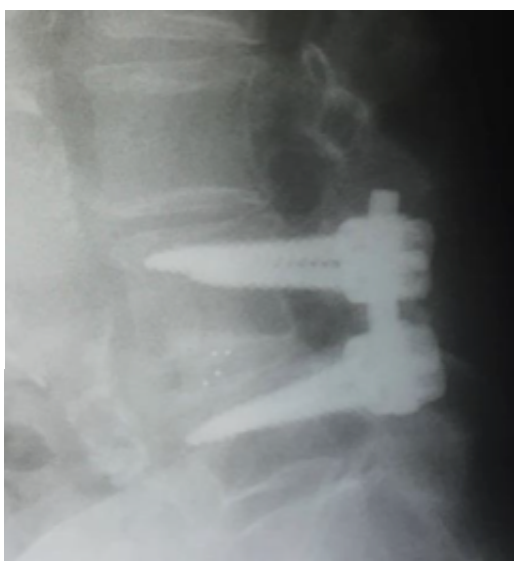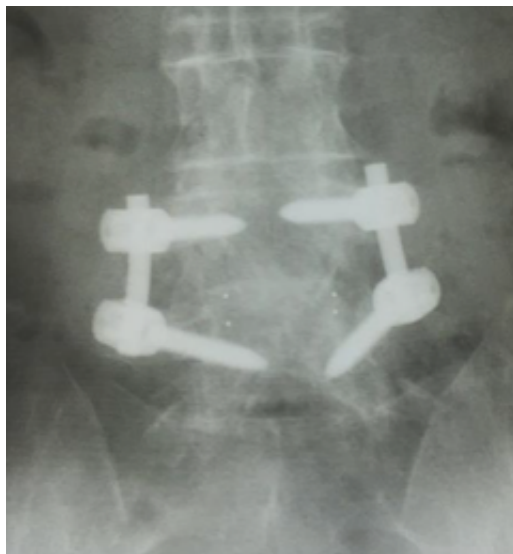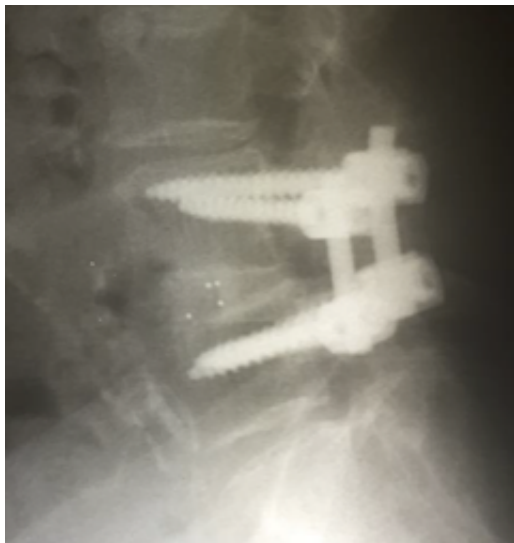Pt # 2 - CES HA CAGE IMAGES - 10 WEEKS




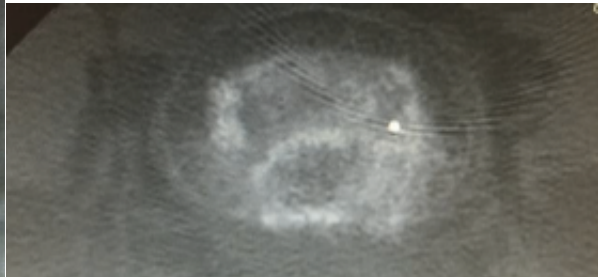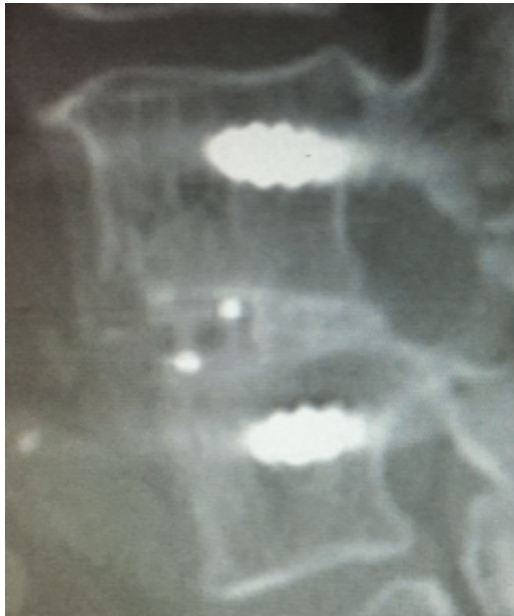


PT - #4 - CES HA CAGES - 6 WEEK / 12 ~~W~~ WEEK XRAY -
24 WEEK CT SCANS

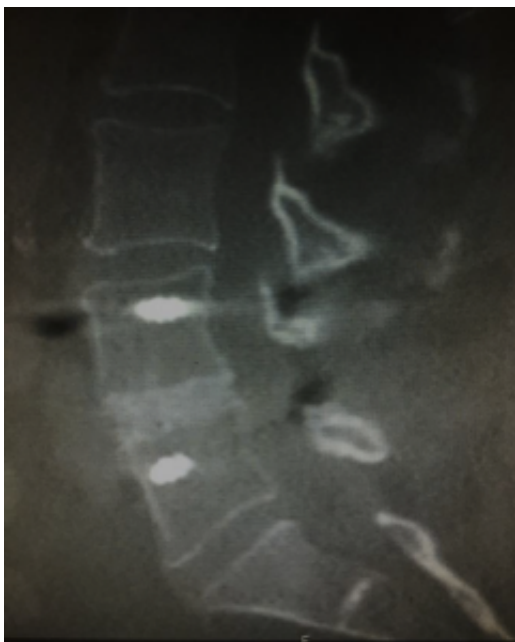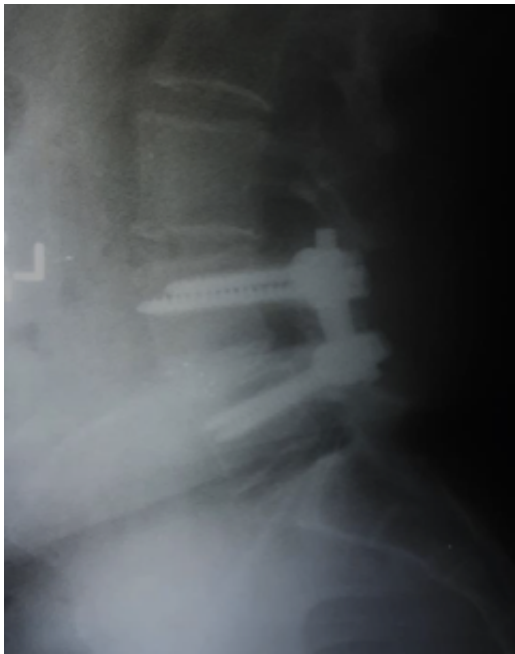6 WEEKS




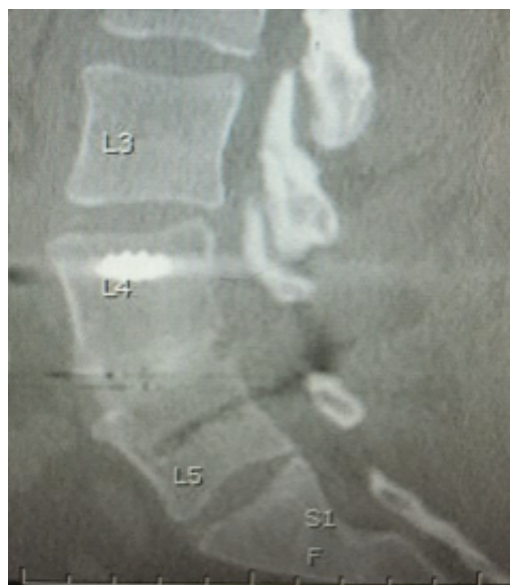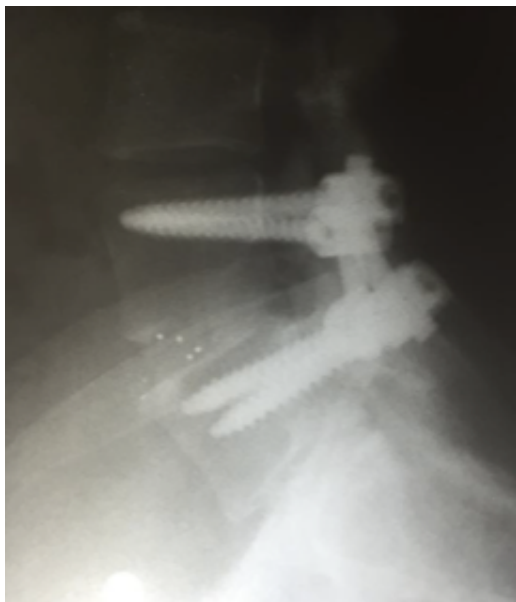24 WEEK CT SCANS



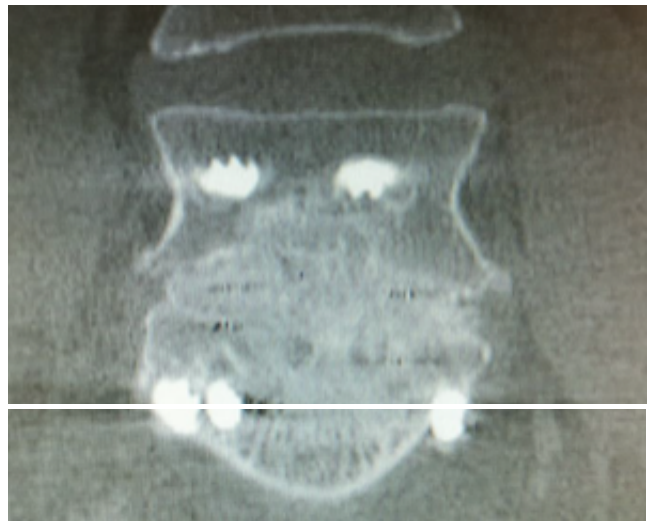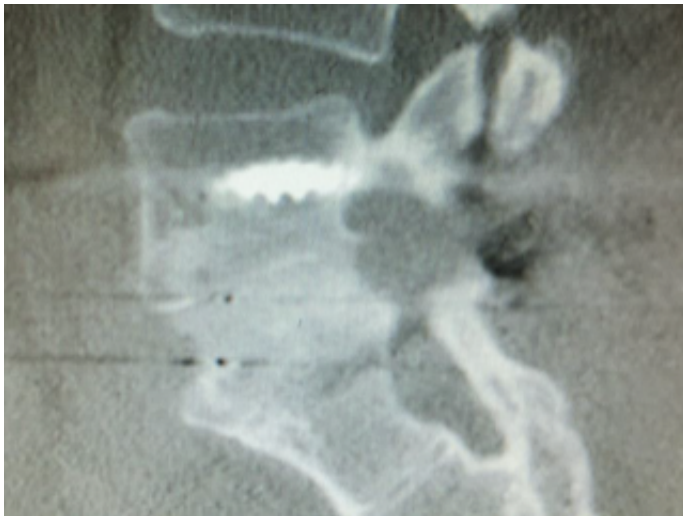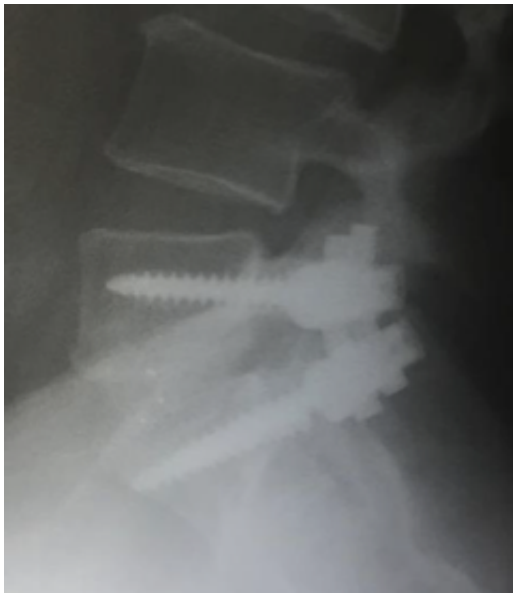PT # 5 - CES HA CAGES - 6 WEEK XRAY /
24 WEEK CT SCAN




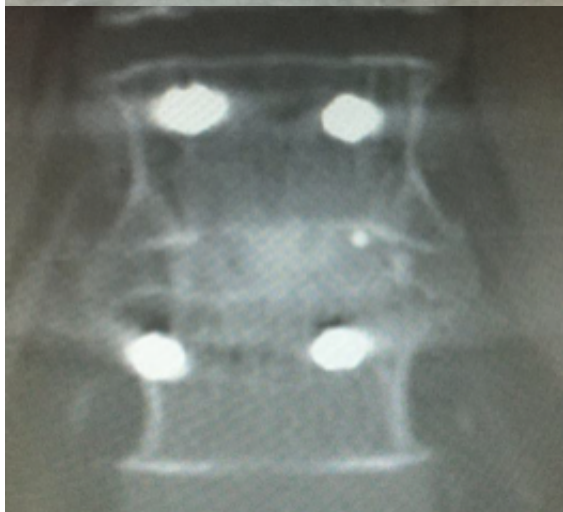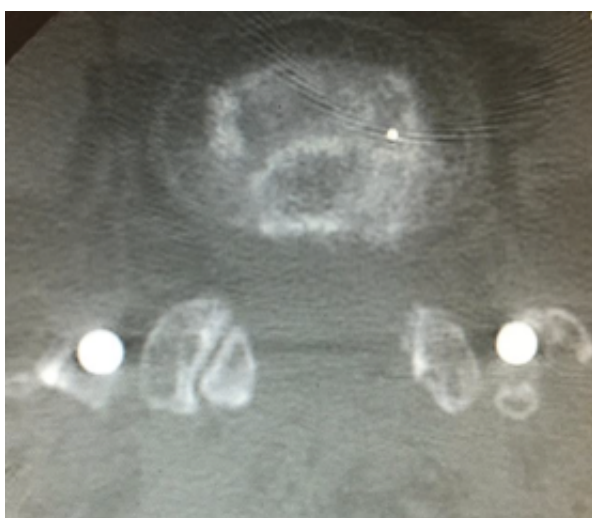
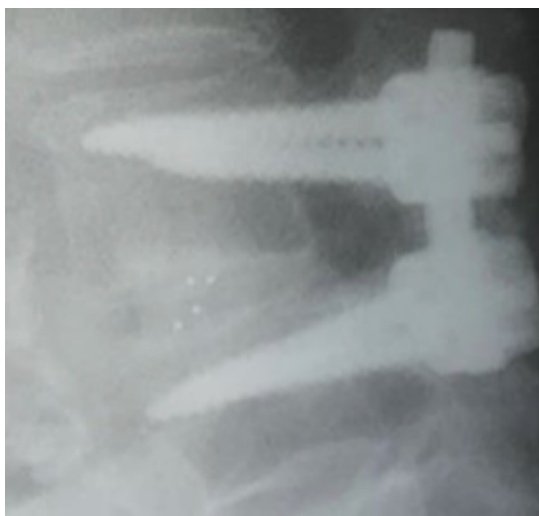PT# 6 - CES HA CAGES - 6 WEEKS 
XRAY / 24 WEEK CT SCAN



PT #7 - CES HA CAGES - 12 WEEK
XRAY - 24 WEEK CT

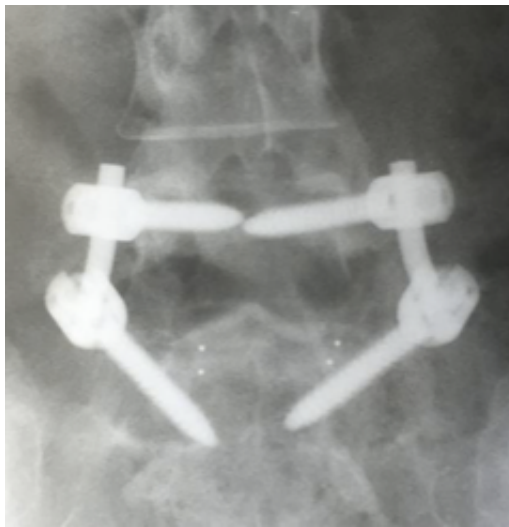
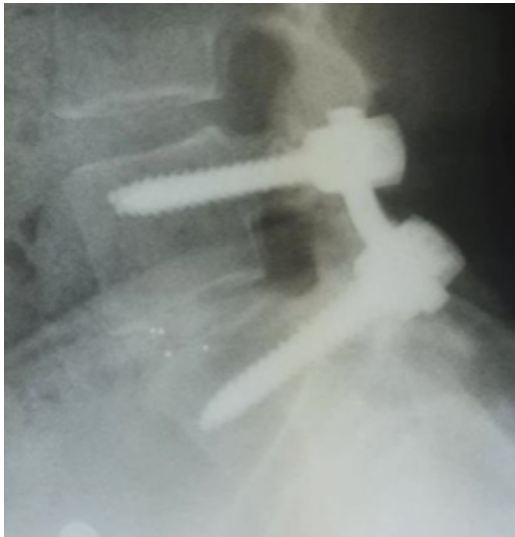
PT # 8 - CES HA CAGES - 
12 WEEK XRAY / 24 WEEK CT SCAN

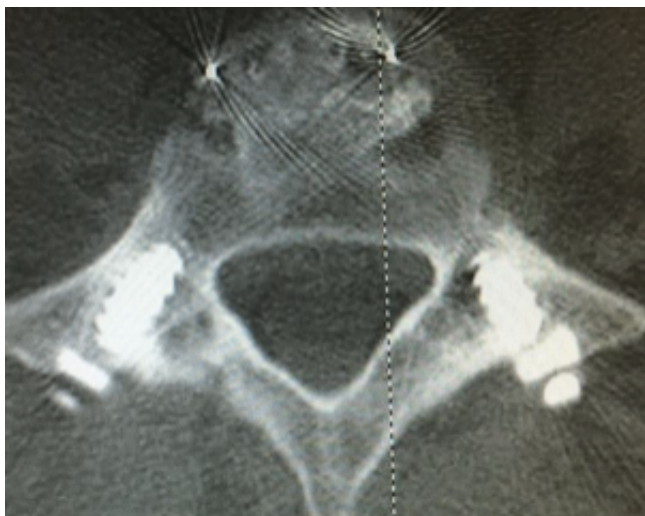

PT #9 - CES HA CAGES - 12 WEEKS RAY -
24 WEEK CT SCAN

12 WEEKS

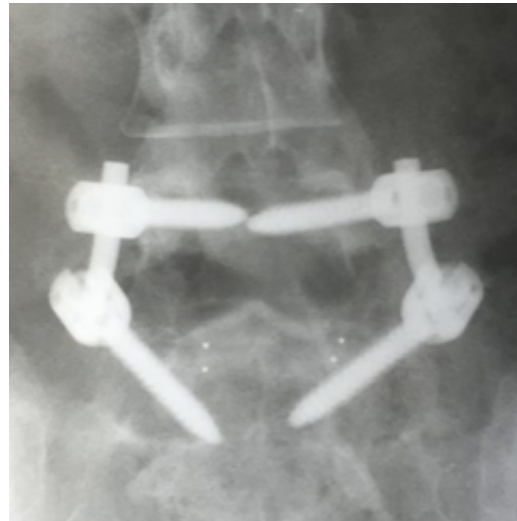
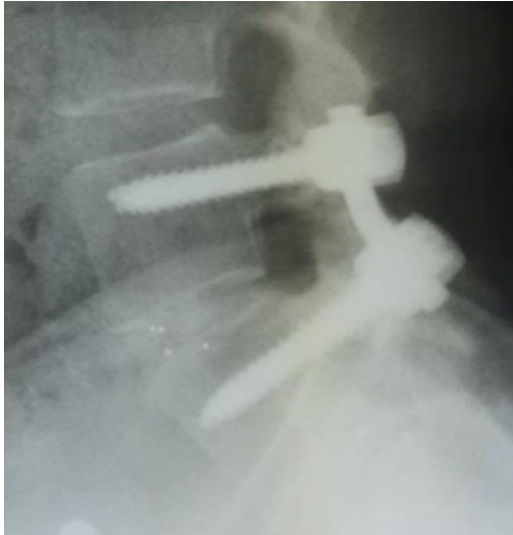

24 WEEK CT SCANS

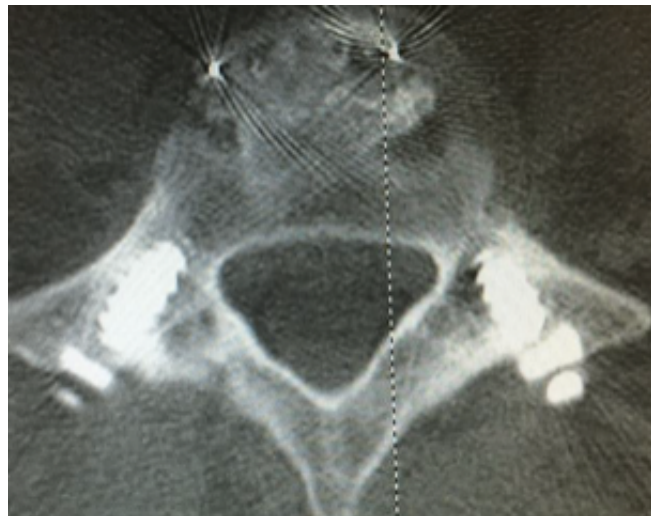
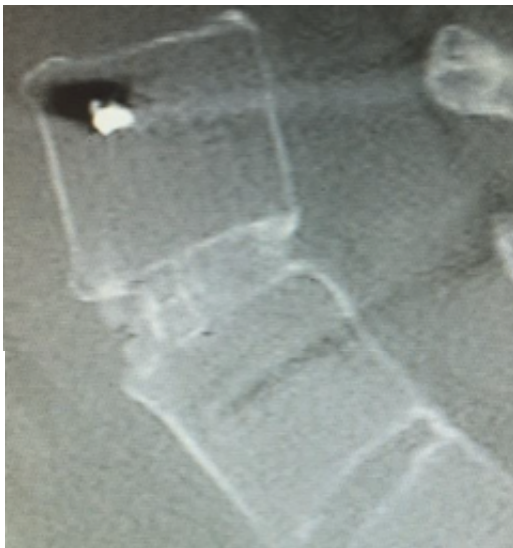
PT# 10 CES HA CAGES - 12 WEEKS RAY-24 WEEK CT
SCAN

12 WEEKS

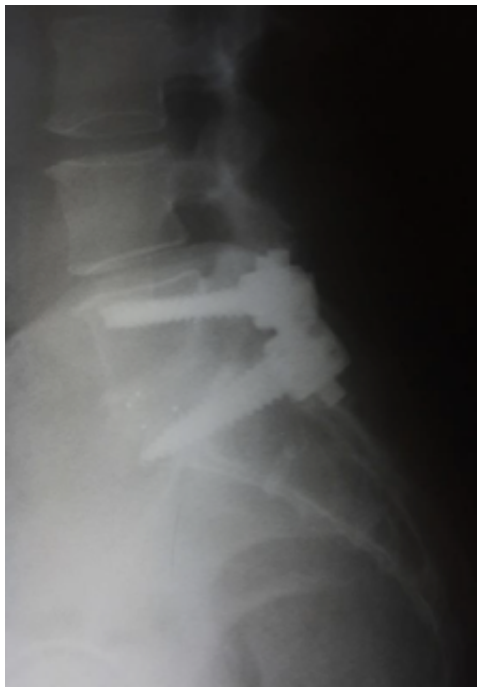

24 WEEK CT SCANS

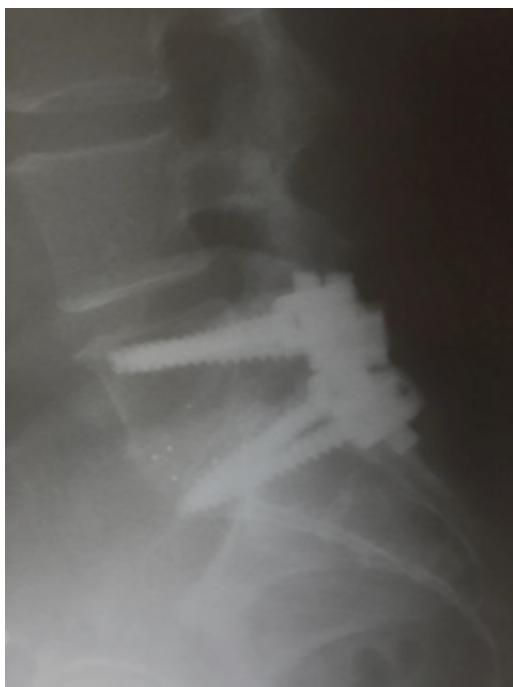

PT # 11 - CES HA ENHANCED CAGE @ 6 WEEK / 12
WEEK XRAY - 24 WEEK CT

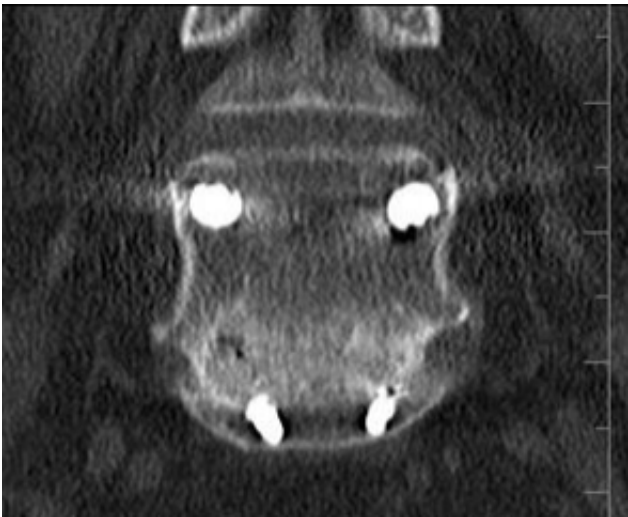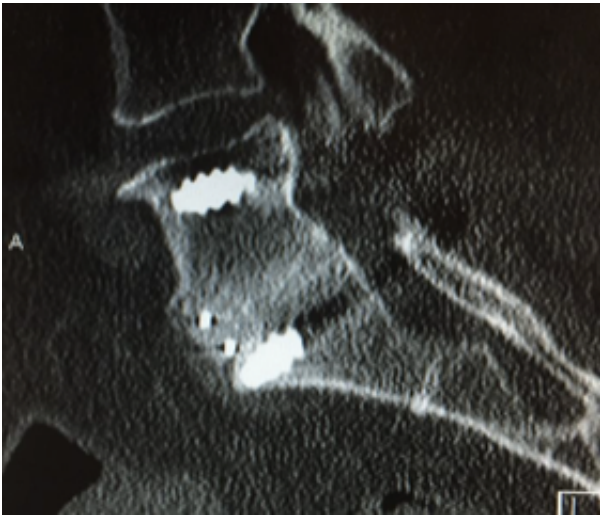6WEEKS



12 WEEKS

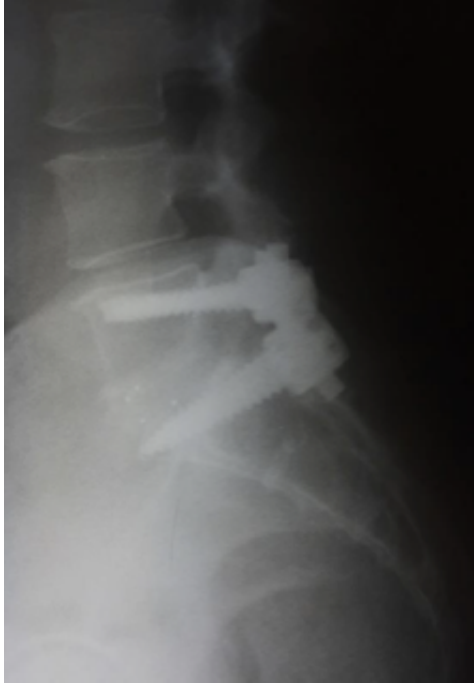

24 WEEK CT SCAN

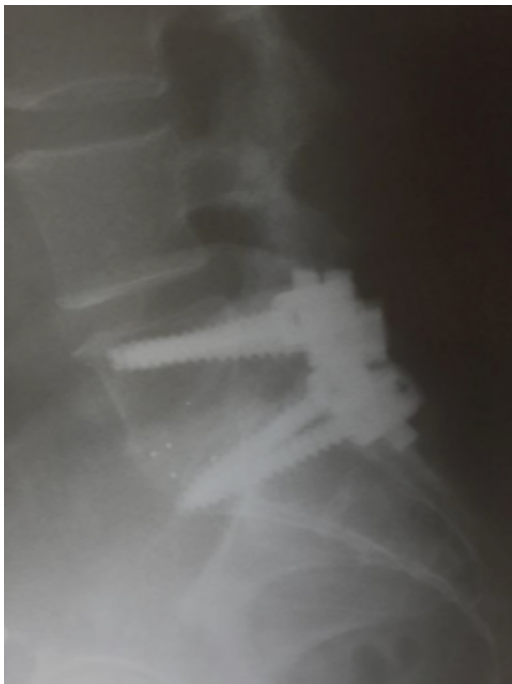

PT # 12 - CES HA ENHANCED CAGES - 6 WEEK / 12
WEEK XRAY - 24 WEEK CT

6WEEKS



12 WEEKS



24 WEEK CT SCAN

