

# Rationale, characteristics, and clinical performance of the OsteoSponge<sup>®</sup>: a novel allograft for treatment of osseous defects

Larry E Miller<sup>1,2</sup>

David J Jacofsky<sup>3</sup>

Kelly R Kirker<sup>4</sup>

Kristin L Fitzpatrick<sup>5</sup>

Gregory A Juda<sup>6</sup>

Jon E Block<sup>2</sup>

<sup>1</sup>Miller Scientific Consulting, Arden, NC, USA; <sup>2</sup>Jon Block Group, San Francisco, CA, USA; <sup>3</sup>CORE Institute, Phoenix, AZ, USA; <sup>4</sup>Center for Biofilm Engineering, Bozeman, MT, USA; <sup>5</sup>Department of Biological Structure, University of Washington, Seattle, WA, USA; <sup>6</sup>Bacterin International, Belgrade, MT, USA

**Abstract:** A variety of bone grafts and bone graft substitutes, each with distinctly different characteristics, is available to the orthopedic surgeon for various reconstructive procedures. However, adequate reconstruction of osseous defects remains a therapeutic challenge. Each bone graft option has a unique set of benefits and risks that must be considered in relation to the particular pathology, and to patient characteristics and comorbidities, in order to achieve the best possible outcome. The OsteoSponge<sup>®</sup> allograft consists of 100% demineralized human cancellous bone, with no additional carrier materials. The OsteoSponge is compressible, allowing precise graft placement in most osseous defects; subsequent expansion completely fills the void. The material is prepared using methods that preserve native growth factors, thereby promoting cellular ingrowth, proliferation, and ultimately osteogenesis. Preliminary evidence suggests that the OsteoSponge matrix is safe and effective when used in surgical treatment of osseous defects. This article describes the rationale for, and characteristics of, the OsteoSponge, and summarizes the results from preclinical and human studies.

**Keywords:** allograft, bone graft, demineralized bone, osseous defect, OsteoSponge

## Introduction

Bone is among the most commonly transplanted tissues in the human body, with approximately 600,000 grafting procedures performed each year.<sup>1</sup> A variety of bone grafts and bone graft substitutes are available for use in repairing osseous defects (eg, cavitary void filling following tumor and cyst resection and curettage), as well as for augmentation of osseous fusion. However, choosing the most appropriate bone graft is often a difficult decision, since each graft type has distinct strengths and limitations, and because additional factors must be considered, including the environment of the defect site, loading magnitude, and systemic host factors.

The ideal bone graft exhibits four characteristics that mimic native bone: osteoconduction, osteoinduction, osteointegration, and osteogenicity.<sup>2,3</sup> Osteoconduction is the ability of a bone graft to act as a passive scaffold that allows both neovascularization and graft infiltration by osteogenic precursor cells and/or osteoblasts, via creeping substitution. Osteoblastic and osteoclastic cellular activity remodel such grafts through a porous graft scaffold. The microporosity and interconnectivity of the pores are important in allowing neoangiogenesis to supply cells in the deeper aspect of the graft, and for essential communication between bone cells within the scaffold milieu. Osteoinduction refers to the ability to recruit mesenchymal cells, via chemotaxis, and stimulate them to differentiate into osteoblasts and proliferate. Osteointegration refers to the ability of the graft to chemically bond with the surface

Correspondence: Jon E Block  
The Jon Block Group, 2210 Jackson  
Street, Suite 401, San Francisco,  
CA 94115, USA  
Tel +1 415 775 7947  
Fax +1 415 928 0765  
Email [jonblock@jonblockgroup.com](mailto:jonblock@jonblockgroup.com)

of native bone, in the absence of an intervening layer of fibrous tissue. Osteogenicity describes the ability of a graft to produce new bone, due to the presence of viable osteoprogenitor cells within the graft.<sup>2,4,5</sup>

A strict comparison of treatment success for different types of bone graft in osseous defect treatment is confounded by variation in the types and locations of the defects, and hampered by the paucity of comparative studies. Nonetheless, a brief discussion follows of the strengths and limitations of different types of bone graft for the treatment of osseous defects.

## Autologous bone grafts

Historically, autografts have been the mainstay bone graft type for treatment of osseous defects. The iliac crest is easily accessible for obtaining graft material, and the characteristics of autografts are ideal. However, the use of autografts is limited by the potential for morbidity at the harvest site, and by the difficulty of filling large voids.<sup>6</sup> Obtaining large quantities of autograft material may result in prolonged postoperative pain and ambulatory difficulty, since the risk of morbidity after autografting is directly proportional to the volume of bone excised.<sup>7</sup> Autologous bone has limited utility for the treatment of osseous defects: it has a relatively poor risk-to-benefit ratio, because other bone graft choices do not have the potential for complications at the harvest site (eg, infection, neuroma, hypertrophic or painful scar, pelvic fracture, requiring reparative surgery, and hematoma, requiring secondary evacuation).

## Xenografts

Xenografts have limited utility for osseous defect reconstruction, primarily due to their unsatisfactory effectiveness and their safety risks.<sup>8,9</sup> Xenografts promote osteoconduction, although this also compromises the initial stability of the graft.<sup>10</sup> Autoclaving of the graft lowers its compression resistance by up to 70%,<sup>11</sup> yet does not eliminate the risks of infection and graft rejection.<sup>12</sup> The need for long-term immunosuppressive therapy, with associated side-effects, makes the xenograft a poor choice for the treatment of osseous defects.<sup>13</sup>

## Ceramic bone graft substitutes

Ceramic bone graft substitutes have varying biomechanical properties but, as a whole, they suffer from common limitations.<sup>14</sup> Generally, ceramic bone graft substitutes have limited mechanical properties. They are used in nonweight-bearing sites, in conjunction with internal or external fixation devices. The bending strength of the hydroxyapatite

incorporated in cortical bone is only 10% of that of the bone itself. Therefore, the bone graft may be unable to withstand normal physiological loads.<sup>15</sup> Residual hydroxyapatite material remains unincorporated for 10 years or more following grafting and is often considered by surgeons to be a semipermanent implant.<sup>16</sup> The cost of ceramic bone graft substitutes can be high, especially for the treatment of large defects.<sup>17</sup>

## Undemineralized allografts

Allografts have distinct advantages over other graft types for the treatment of osseous defects: lack of morbidity at the harvest site, simple technique with short operative time, sufficient supply to treat large bone voids, and excellent patient outcomes.<sup>18</sup> Processed allografts have the same structure as native bone, and exhibit a uniform ability to withstand intraoperative handling and mechanical loading. Allografts are widely available, and are versatile, since the shape, contour, and mineral density can be modified to the particular clinical indication.

However, undemineralized allografts also suffer from several limitations. Allograft fracture or nonunion has been reported in 15%–20% of grafts, due primarily to limited revascularization.<sup>19</sup> In large defects, poor anatomical matching between graft and host defect can alter joint kinematics and load distribution, which may accelerate bone resorption or joint degeneration. The difficulty of milling a bulk allograft to precisely fit a defect site leads to less-than-ideal contact areas at the host-graft junction. Allograft infection has been reported in 6%–13% of cases, with the proximal tibia most commonly affected.<sup>19,20</sup>

Allografts, obtained from deceased donors, or from femoral heads during hip arthroplasty, are widely used for various orthopedic reconstructive applications, and have osteoconductive, osteoinductive, and osteointegrative properties. However, a major limitation of allograft bone is the absence of osteogenic properties, due to an absence of live cells. Demineralized bone matrix (DBM) is a unique type of allogenic bone graft with greater osteoinductive properties, compared to undemineralized allografts. The demineralization process exposes growth factors within the scaffold, allowing them to more easily interact with host cells.<sup>21,22</sup> Furthermore, DBM is comprised mainly of cortical bone, and therefore exhibits greater osteointegration in host bone. Several different types of DBM are currently available, each with slightly different attributes. The aim of this paper is to describe the characteristics and clinical performance of a novel cancellous DBM: OsteoSponge® (Bacterin International, Belgrade, MT).

## OsteoSponge demineralized bone matrix

### OsteoSponge characteristics

OsteoSponge is a novel demineralized cancellous bone matrix that possesses, when combined with bone marrow aspirate (BMA), many desirable attributes for its use in bone grafting.<sup>23</sup> Unlike other DBM putties and gels that contain significant concentrations of exogenous carriers, the OsteoSponge allograft consists of 100% demineralized human cancellous bone, with no additional carrier materials. Demineralization gives the OsteoSponge the ability to conform to irregular shapes and to compress into a variety of bone voids (Figure 1). Once compressed and inserted into a bone void, the graft then expands to completely fill the contours of the void, thereby enhancing connectivity at the graft–void interface, and exposing the native growth factors (eg, vascular endothelial growth factor, transforming growth factor- $\beta$ , platelet-derived growth factor) and bone morphogenetic proteins (BMPs) that are critical for osteogenesis. The OsteoSponge readily absorbs fluids such as blood and BMA, and will not migrate from the intended surgical site – a potential drawback with other, less viscous DBM putties and gels. The OsteoSponge maintains the natural interconnected porosity of cancellous bone, which provides an ideal scaffold for cellular infiltration and bone formation. The cancellous bone structure matches the same pore size and interconnected porosity that are observed in normal, living host bone. It possesses, therefore, an ideal scaffold morphology.

### OsteoSponge processing

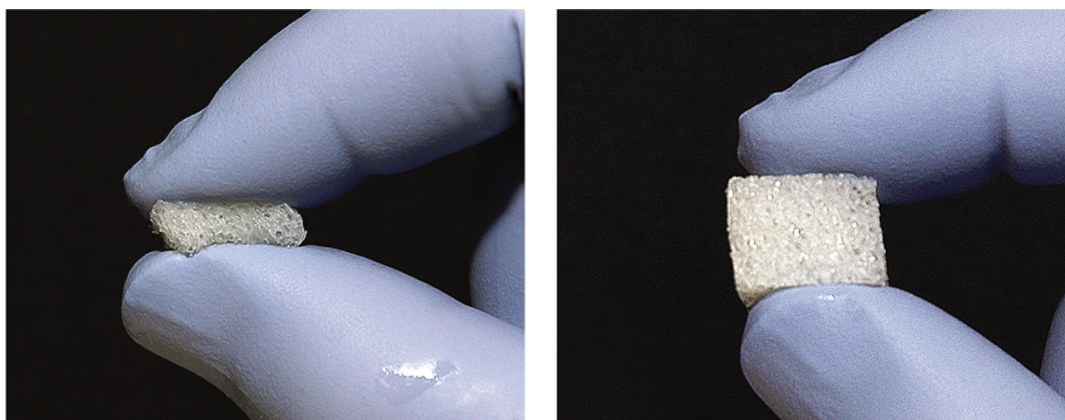
OsteoSponge is manufactured in a tissue-processing facility accredited by the American Association of Tissue Banks

and registered with the US Food and Drug Administration. The graft material is prepared using methods that preserve native growth factors, which promote cellular ingrowth, proliferation and ultimately osteogenesis. The steps involved in processing OsteoSponge allograft include removal of antigenic cells and lipids, via a series of solvent treatment steps; reduction of tissue-associated bioburden, using validated decontamination procedures; and demineralization, via a proprietary process.

The graft then undergoes preservation by lyophilization, which minimizes allograft degradation, which may result from hydrolytic and oxidation reactions.<sup>24</sup> Freeze drying, from the frozen state, also helps to prevent protein denaturation that can occur during air drying.<sup>24</sup> Lyophilization of the graft material allows for storage of the graft at room temperature for up to 5 years, with no deterioration in mechanical or osteoinductive properties. The graft undergoes final packaging aseptically, and terminal sterilization by low-dose gamma irradiation. These processing steps eliminate or minimize exposure of the allografts to factors known to adversely impact their biologic performance.<sup>25</sup>

### Native growth factors in OsteoSponge

Extracts of OsteoSponge blocks, processed from a 27-year-old male donor, were evaluated with enzyme-linked immunosorbent assays to determine the concentrations of native growth factors. The values obtained were  $8423 \pm 248$  pg/g for human BMP-2, (hBMP-2),  $1112 \pm 19$  pg/g for hBMP-4,  $50581 \pm 1876$  pg/g for hBMP-7, and  $713 \pm 173$  pg/g for insulin-like growth factor 1. These results illustrate that OsteoSponge provides a substantial quantity of the signaling molecules responsible for osteoblastic and osteoclastic differentiation.



**Figure 1** Demonstration of compressible handling characteristics of OsteoSponge following rehydration.

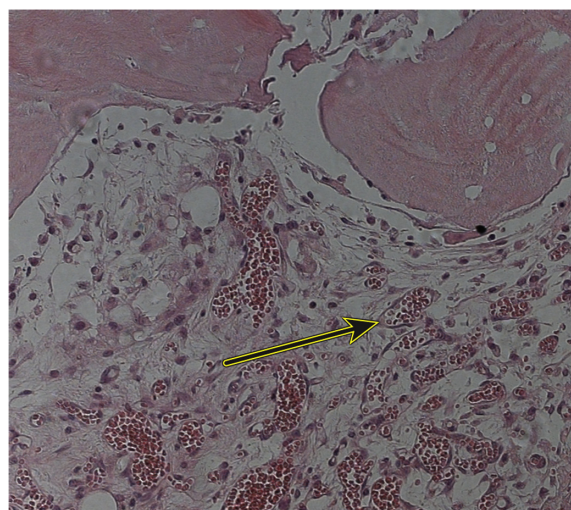
**Notes:** (Left) OsteoSponge can be compressed to 1/3 of its original size in order to fit a space; (Right) OsteoSponge springs back to fill the void without losing its original strength or shape.



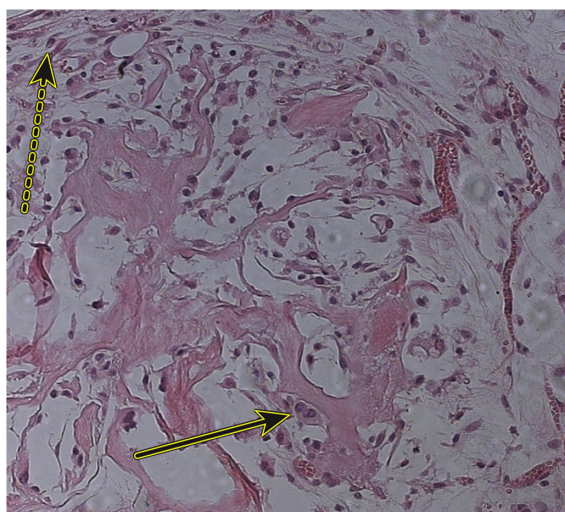
## Clinical studies

Several unpublished clinical studies have been performed with the OsteoSponge in various orthopedic and spinal surgery applications.

Preclinical evidence of the osteogenic activity of OsteoSponge was demonstrated in a study using an athymic nude mouse transplantation model. Equal volumes of three DBM materials were surgically implanted in mice: OsteoSponge, Grafton® (Osteotech, Eatontown, NJ), and (AlloSource™ Demineralized Cancellous Cube; AlloSource™, Centennial, CO). The tissue was then explanted at 2 and 4 weeks. At week 2, the OsteoSponge group demonstrated robust neovascularization (Figure 2), noticeable stroma, osteoclastic activity, and production of osteoid (Figure 3) – findings that are consistent with early bone healing. By contrast, Grafton (Figure 4) and AlloSource Demineralized Cancellous Cube (Figure 5) demonstrated limited activity in surrounding tissue, no neovascular formation, and little evidence of osteoclastic activity or cell attachment to DBM particles. At week 4, OsteoSponge specimens showed progressive neovascularization with osteoid and new bone formation, frequent rimming of DBM with osteoblasts, evidence of ongoing osteoclast activity, and repopulation of the DBM with new cells (Figure 6). Overall, OsteoSponge demonstrated excellent biocompatibility and osteoinductivity. It served as a more favorable matrix for cellular infiltration and bone regeneration in early-term follow-up, by comparison with other DBM grafts. In a separate study, using an athymic rat model, OsteoSponge was implanted at an intramuscular site for 28 days. Histological examination revealed significant osteoinductive properties.

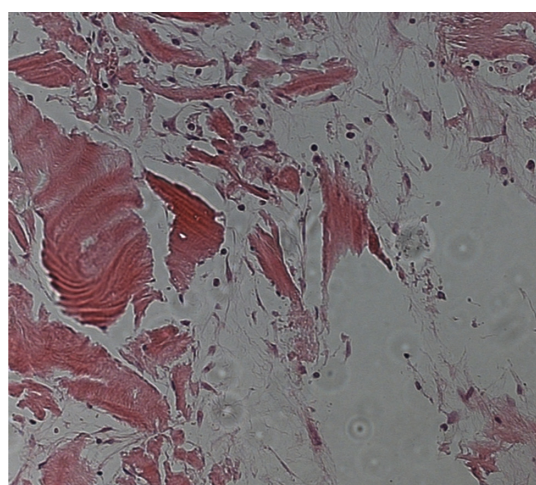


**Figure 2** Histologic explant specimens, demonstrating robust neovascularization (solid arrow) with OsteoSponge 2 weeks after implantation.



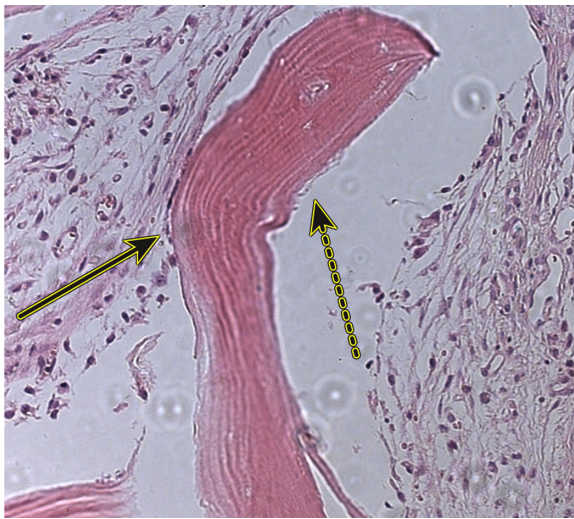
**Figure 3** Histologic explant, demonstrating an active stroma (dotted arrow), remodeling activity, and production of osteoid (solid arrow) with OsteoSponge 2 weeks after implantation.

OsteoSponge has demonstrated excellent clinical performance in bone voids, nonunion sites, and spinal fusion surgery (Figure 7). A prospective series of 45 patients (53% women; mean age 53 years) was treated with anterior discectomy and fusion, using anterior plating and polyetheretherketone (PEEK) interbody cages. OsteoSponge cubes were mixed with autologous BMA, extracted from an adjacent vertebral body, and compressed into the PEEK cage. At 2 years post-treatment, solid fusion was achieved in all patients, with no evidence of screw or plate loosening, plate lift-off, breakage, subsidence, or cage dislodgement. Adverse events were noted in three (6.7%) patients. One patient showed mild resorption at an endplate, with no loss of fixation or alignment.



**Figure 4** Histologic explant specimens, demonstrating limited activity in surrounding tissue, no neovascular formation, and little evidence of osteoclastic activity or cell attachment to the DBM particles with Grafton®, 2 weeks after implantation.



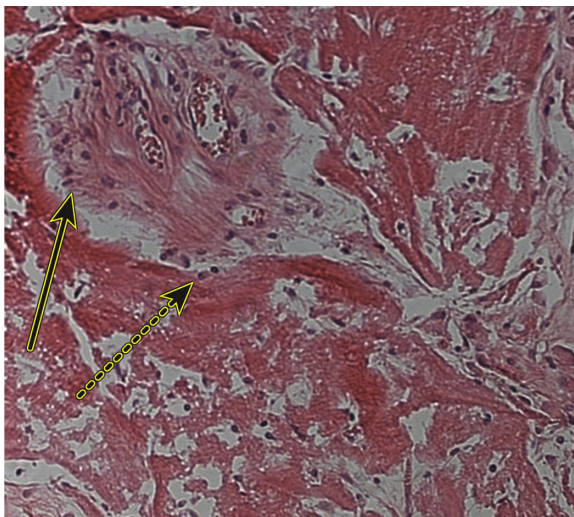


**Figure 5** Histologic explant, demonstrating sparse cell attachments, rimming osteoblasts, or associations with the Allosource™ DBM material (solid arrow) and a majority of DBM surface area revealing no host interaction (dotted arrow).

**Notes:** There is no evidence of neovascularization or osteoclastic activity with Allosource Demineralized Cancellous Cube 2 weeks after implantation.

A second patient developed an immediate postoperative hematoma and breathing difficulty after a three-level procedure; treatment consisted of hematoma evacuation and vessel ligation. A third patient developed a superficial wound infection that required readmission and intravenous antibiotics, with no requirement for surgical debridement.

A prospective randomized study compared OsteoSponge plus BMA (N = 16) and recombinant hBMP-2 (rhBMP-2) (N = 12) in 28 patients who underwent posterior lumbar interbody spinal fusion surgery, with placement of two



**Figure 6** Histologic explant of OsteoSponge at 4 weeks after implantation.

**Notes:** This specimen demonstrates progressive neovascularization with osteoid and new bone formation within the pores of the DBM sponge (solid arrow), with frequent rimming of DBM with osteoblasts (dotted arrow), evidence of ongoing osteoclastic activity, and repopulation of the OsteoSponge DBM with host cells.

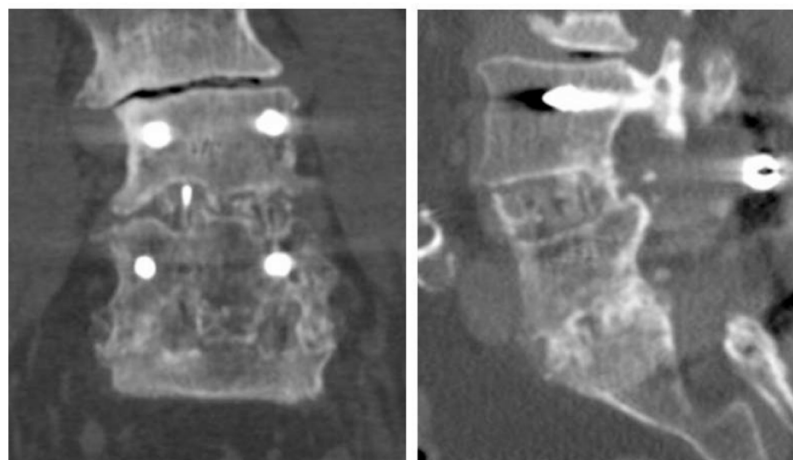
PEEK cages per fused level.<sup>26</sup> Bone graft material was placed within and between the PEEK cages. A posterolateral fusion using Actifuse™ (Apatech, Elstree, UK), soaked in BMA, along with posterior instrumentation, completed the circumferential procedure. Quality of life surveys and radiographs were obtained at baseline and at regular intervals for 2 years. Computed tomography was performed at 1 and 2 years, postoperatively. There were no pseudoarthroses or hardware failures in either group. OsteoSponge plus BMA performed similarly to rhBMP-2 in achieving anterior fusion. At 2 years, the average fusion density, was 199 Hounsfield units (HU) for the OsteoSponge group, and 251 HU for the rhBMP-2 group ( $P = 0.06$ ). The average fusion density for both groups was greater than that of the adjacent vertebral bodies. The volume of new bone formed within the disc space, assessed using computed tomography, indicated no difference between groups. At year 1, the rhBMP-2 group exhibited a marked difference in the occurrences of leg pain, in contrast to the OsteoSponge group ( $P < 0.001$ ), but this difference normalized at year 2. Quality of life measures and the Oswestry Disability Index showed no statistical difference between the groups at 2 years.

Overall, preliminary evidence from preclinical and clinical observations suggests that the OsteoSponge matrix is safe and effective when used in surgical treatment of osseous defects.

## Discussion

The OsteoSponge demineralized cancellous allograft has been shown to induce new bone formation in in vitro animal studies and in clinical settings, with no observed safety risks. This contrasts with materials such as autograft, xenograft, and ceramic bone graft substitutes, which have been used with mixed success.

Clinical experience with autografts for the treatment of osseous defects has yielded mixed results. Rajan et al treated 75 patients, who had comminuted distal radius fractures, either with autograft or allograft. They reported similar clinical and radiographic outcomes at 1 year in each group.<sup>27</sup> Ring and colleagues treated 35 patients, who had diaphyseal forearm nonunions and segmental defects, with autografts and plate fixation. All patients were healed, and none required a follow-up procedure within 6 months post-treatment.<sup>28</sup> Autografts have been shown to yield good-to-excellent results in 90% of cystic talus lesions.<sup>29</sup> However, several trials have reported mixed outcomes with autologous bone grafting. Union rates following comminuted forearm fracture were similar in patients treated with or without autograft.<sup>30,31</sup>



**Figure 7** Computed tomography scan (AP: left; lateral: right), demonstrating solid two-level lumbar fusion using OsteoSponge allograft in a 64-year-old female smoker.  
**Abbreviation:** AP, anteroposterior.

Gershuni and Pinsker<sup>32</sup> treated 40 tibial nonunions with autograft and cast immobilization. Despite a union rate of 85%, significant tibial deformity persisted. Adani et al<sup>33</sup> treated 13 patients with autograft for humeral nonunion, and reported additional bone grafting in 31% of patients at 6-month follow-up.

Perhaps the primary limitation of autografts is the persistent morbidity associated with harvesting at the donor site (typically, the iliac crest).<sup>6</sup> The most common complication is postoperative pain at the donor site, reported in 50% of patients and persisting through year 1 in up to 29% of patients.<sup>27,34</sup> Consequently, autologous bone grafting has fallen out of favor in recent years.

Few human studies of osseous defect treatment with xenografts have been conducted.<sup>9</sup> Schultheiss et al reported delayed incorporation of bovine cancellous blocks for the reconstruction of thoracolumbar fractures, compared with autologous tricortical iliac crest bone grafts.<sup>8</sup> Liu et al<sup>35</sup> treated 65 patients with xenograft, predominantly for long bone fractures and tumor resection. Graft infection was reported in 8% of cases. Graft rejection with immunosuppressive treatment was common. Charalambides and colleagues<sup>12</sup> treated 27 patients with xenograft and autograft following hip revision surgery. After a mean 2.5 year follow-up, three

grafts did not incorporate, three patients had graft infection, and one patient suffered a deep prosthesis infection. Levai et al<sup>36</sup> used bovine xenograft in 31 patients for the treatment of tibial osteotomy defects. At 2.5 years follow-up, five (16%) patients experienced local discharge or infection. Overall, xenografts are not recommended for filling cavitory defects, due to the high risks of graft rejection and infection.

Ceramic bone graft substitutes yield acceptable long-term clinical outcomes.<sup>14</sup> Coralline hydroxyapatite has demonstrated clinical outcomes similar to that of autograft in treating tibial plateau fractures.<sup>37</sup> However, the brittleness of this material makes handling difficult, and often results in fragmentation during incorporation into the defect. Several authors have reported excellent results with calcium phosphate for traumatic fractures, and for cavitory filling after excision of tumors or cysts.<sup>38,39</sup> Anker and colleagues<sup>40</sup> reported that tricalcium phosphate incorporated well into small cavitory defects, but that incorporation was incomplete after 1 year in large defects.

Calcium phosphate cement has much greater compressive strength than other ceramics. A prospective trial of 110 patients with distal radius fractures found that calcium phosphate cement yielded a greater frequency of satisfactory results, and fewer malunions, when used to fill metaphyseal defects than

**Table 1** Characteristics of bone grafts and bone graft substitutes

Variable	Osteosponge	Undemineralized allograft	Autograft	Xenograft	Ceramics
Osteoconduction	+++	+++	+++	+++	++
Osteoinduction	+++	++	+++	+	–
Osteointegration	+++	++	+++	++	+++
Osteogenesis	++	–	+++	–	–

**Abbreviations:** +++, excellent; ++, average; +, poor; –, none.

**Table 2** Clinical evaluation of osseous defect treatment with allograft, autograft, xenograft, and ceramics

Variable	Osteosponge	Undemineralized allograft	Autograft	Xenograft	Ceramics
Structural support	+	+++	++	++	++
Cost effectiveness	+++	+++	++	+	++
Procedural safety	+++	+++	+	+	++
Long-term safety	+++	+++	+	?	?
Long-term effectiveness	+++	+++	++	?	+

**Abbreviations:** +++, excellent; ++, average; +, poor; ?, unknown.

when used for closed reduction and cast immobilization.<sup>41</sup> A similar study in 52 menopausal, osteoporotic women with unstable distal radius fractures showed that the use of calcium phosphate cement to supplement pin and screw fixation maintained the reduction of unstable distal radius fractures, and yielded superior clinical outcomes relative to percutaneous pinning.<sup>42</sup> However, a randomized study of 323 patients with distal radius fractures, treated with or without calcium phosphate cement for metaphyseal defect filling, showed no group differences in grip strength, range of motion, or quality of life at 3 months and at 1 year.<sup>43</sup> Furthermore, extravasation into the surrounding soft tissues occurred in 70% of patients treated with calcium phosphate cement. Painful soft tissue reactions have been reported in up to 20% of patients following calcium phosphate cement injection.<sup>44</sup>

The use of calcium sulfate for osseous defects remains controversial. This material undergoes dissolution within 4 to 12 weeks, which is too rapid to provide a long-term framework to support osteoconduction. Calcium sulfate ceramics undergo phagocytosis, which contributes to accelerated biodegradation.<sup>45</sup> Consequently, outcomes of tibial defect treatment with calcium sulfate are similar to those arising from no treatment at all.<sup>46</sup> Collagraft (Zimmer, Warsaw, IN), a composite of bovine collagen and a biphasic ceramic (60% hydroxyapatite, 40% tricalcium phosphate), was shown to perform similarly to autograft in a randomized controlled trial of 325 patients with long bone fractures, followed for 2 years, although allergic response to the bovine protein occurred in 1 out of 10 cases.<sup>47</sup>

An evaluation of the characteristics and clinical performance of OsteoSponge in relation to other bone grafts and bone graft substitutes for osseous defect treatment is provided in Tables 1 and 2.

OsteoSponge is a nonstructural graft. Therefore, it must be used in conjunction with hardware or other graft material to provide structural support, if needed. Caution should be exercised if the patient is allergic to any antibiotics or chemicals used in processing and testing. The presence of infection at the transplantation site is a contraindication for

the use of this allograft. Long-term comparative trials are recommended to further clarify the safety and effectiveness of OsteoSponge for the treatment of osseous defects.

Overall, the OsteoSponge allograft exhibits ideal properties for bone regeneration, similar to those of autografts. However, the OsteoSponge has a distinct advantage over autografts, in that there is no risk of complications at the harvest site, or donor pain postoperatively. Additional clinical experience with long-term follow-up is anticipated, in order to fully establish evidence for the durability of this novel grafting material. The OsteoSponge DBM is a promising bone graft for serving as an adjunct to the treatment of osseous defects.

## Acknowledgments

We acknowledge Scott C Miller for assistance in histopathology interpretation, and Randy Asher for graphical assistance.

## Disclosures

David Jacofsky is a paid consultant to Bacterin International. Gregory Juda is an employee of Bacterin International. Larry Miller and Jon Block are consultants to Bacterin International. The authors report no other conflicts of interest in this study.

## References

1. Marino JT, Ziran BH. Use of solid and cancellous autologous bone graft for fractures and nonunions. *Orthop Clin North Am.* 2010;41(1):15–26.
2. Calori GM, Mazza E, Colombo M, Ripamonti C. The use of bone-graft substitutes in large bone defects: any specific needs? *Injury.* 2011;42 Suppl 2:S56–S63.
3. Bauer TW, Muschler GF. Bone graft materials. An overview of the basic science. *Clin Orthop Relat Res.* 2000;371:10–27.
4. Giannoudis PV, Chris Arts JJ, Schmidmaier G, Larsson S. What should be the characteristics of the ideal bone graft substitute? *Injury.* 2011;42 Suppl 2:S1–S2.
5. Laurencin C, Khan Y, El-Amin SF. Bone graft substitutes. *Expert Rev Med Devices.* 2006;3(1):49–57.
6. Russell JL, Block JE. Surgical harvesting of bone graft from the ilium: point of view. *Med Hypotheses.* 2000;55(6):474–479.
7. Pape HC, Evans A, Kobbe P. Autologous bone graft: properties and techniques. *J Orthop Trauma.* 2010;24 Suppl 1:S36–S40.
8. Schultheiss M, Sarkar M, Arand M, et al. Solvent-preserved, bovine cancellous bone blocks used for reconstruction of thoracolumbar fractures in minimally invasive spinal surgery—first clinical results. *Eur Spine J.* 2005;14(2):192–196.



9. Block JE, Poser J. Does xenogeneic demineralized bone matrix have clinical utility as a bone graft substitute? *Med Hypotheses*. 1995;45(1):27–32.
10. Su-Gwan K, Hak-Kyun K, Sung-Chul L. Combined implantation of particulate dentine, plaster of Paris, and a bone xenograft (Bio-Oss) for bone regeneration in rats. *J Craniomaxillofac Surg*. 2001;29(5):282–288.
11. Viceconti M, Toni A, Brizio L, Rubbini L, Borrelli A. The effect of autoclaving on the mechanical properties of bank bovine bone. *Chir Organi Mov*. 1996;81(1):63–68.
12. Charalambides C, Beer M, Cobb AG. Poor results after augmenting autograft with xenograft (Surgibone) in hip revision surgery: a report of 27 cases. *Acta Orthop*. 2005;76(4):544–549.
13. Hancock WW. Delayed xenograft rejection. *World J Surg*. 1997;21(9):917–923.
14. Block JE, Thorn MR. Clinical indications of calcium-phosphate biomaterials and related composites for orthopedic procedures. *Calcif Tissue Int*. 2000;66(3):234–238.
15. Bucholz RW. Nonallograft osteoconductive bone graft substitutes. *Clin Orthop Relat Res*. 2002;395(2):44–52.
16. Hak DJ. The use of osteoconductive bone graft substitutes in orthopaedic trauma. *J Am Acad Orthop Surg*. 2007;15(9):525–536.
17. Temple HT, Malinin TI. Microparticulate cortical allograft: an alternative to autograft in the treatment of osseous defects. *Open Orthop J*. 2008;2:91–96.
18. Capanna R, Campanacci DA, Belot N, et al. A new reconstructive technique for intercalary defects of long bones: the association of massive allograft with vascularized fibular autograft. Long-term results and comparison with alternative techniques. *Orthop Clin North Am*. 2007;38(1):51–60.
19. Delloye C, Cornu O, Druet V, Barbier O. Bone allografts: what they can offer and what they cannot. *J Bone Joint Surg Br*. 2007;89(5):574–579.
20. Mankin HJ, Hornicek FJ, Raskin KA. Infection in massive bone allografts. *Clin Orthop Relat Res*. 2005(432):210–216.
21. Moore WR, Graves SE, Bain GI. Synthetic bone graft substitutes. *ANZ J Surg*. 2001;71(6):354–361.
22. Russell JL, Block JE. Clinical utility of demineralized bone matrix for osseous defects, arthrodesis, and reconstruction: impact of processing techniques and study methodology. *Orthopedics*. 1999;22(5):524–531.
23. Block JE. The role and effectiveness of bone marrow in osseous regeneration. *Med Hypotheses*. 2005;65(4):740–747.
24. Galea G, Kearney JN. Clinical effectiveness of processed and unprocessed bone. *Transfus Med*. 2005;15(3):165–174.
25. Block JE. The impact of irradiation on the microbiological safety, biomechanical properties, and clinical performance of musculoskeletal allografts. *Orthopedics*. 2006;29(11):991–996.
26. Huntsman K, Scott S, Berdugo M, Juda G, Roper S. Lumbar interbody fusion with Osteosponge® demineralized allograft in a PEEK cage as compared to fusion with rhBMP-2: long-term post operative assessment. SAS11, April 26–29, 2011; Las Vegas, NV: International Society for the advancement of Spine Surgery; 2011.
27. Rajan GP, Fornaro J, Trentz O, Zellweger R. Cancellous allograft versus autologous bone grafting for repair of comminuted distal radius fractures: a prospective, randomized trial. *J Trauma*. 2006;60(6):1322–1329.
28. Ring D, Allende C, Jafarnia K, Allende BT, Jupiter JB. Ununited diaphyseal forearm fractures with segmental defects: plate fixation and autogenous cancellous bone-grafting. *J Bone Joint Surg Am*. 2004;86-A(11):2440–2445.
29. Scranton PE Jr, Frey CC, Feder KS. Outcome of osteochondral autograft transplantation for type-V cystic osteochondral lesions of the talus. *J Bone Joint Surg Br*. 2006;88(5):614–619.
30. Wright RR, Schmeling GJ, Schwab JP. The necessity of acute bone grafting in diaphyseal forearm fractures: a retrospective review. *J Orthop Trauma*. 1997;11(4):288–294.
31. Wei SY, Born CT, Abene A, Ong A, Hayda R, DeLong WG Jr. Diaphyseal forearm fractures treated with and without bone graft. *J Trauma*. 1999;46(6):1045–1048.
32. Gershuni DH, Pinsker R. Bone grafting for nonunion of fractures of the tibia: a critical review. *J Trauma*. 1982;22(1):43–49.
33. Adani R, Delcroix L, Tarallo L, Baccarani A, Innocenti M. Reconstruction of posttraumatic bone defects of the humerus with vascularized fibular graft. *J Shoulder Elbow Surg*. 2008;17(4):578–584.
34. Fernyhough JC, Schimandle JJ, Weigel MC, Edwards CC, Levine AM. Chronic donor site pain complicating bone graft harvesting from the posterior iliac crest for spinal fusion. *Spine (Phila Pa 1976)*. 1992;17(12):1474–1480.
35. Liu Z, Xia L, Gong W. Preliminary report of xenogenic bone graft for sixty-five cases. *Zhongguo Xiu Fu Chong Jian Wai Ke Za Zhi*. 1998;12(5):309–311.
36. Levai JP, Bringer O, Descamps S, Boisgard S. Xenograft-related complications after filling valgus open wedge tibial osteotomy defects. *Rev Chir Orthop Reparatrice Appar Mot*. 2003;89(8):707–711.
37. Bucholz RW, Carlton A, Holmes R. Interporous hydroxyapatite as a bone graft substitute in tibial plateau fractures. *Clin Orthop Relat Res*. 1989;240(3):53–62.
38. Bucholz RW, Carlton A, Holmes RE. Hydroxyapatite and tricalcium phosphate bone graft substitutes. *Orthop Clin North Am*. 1987;18(2):323–334.
39. McAndrew MP, Gorman PW, Lange TA. Tricalcium phosphate as a bone graft substitute in trauma: preliminary report. *J Orthop Trauma*. 1988;2(4):333–339.
40. Anker CJ, Holdridge SP, Baird B, Cohen H, Damron TA. Ultraporous beta-tricalcium phosphate is well incorporated in small cavity defects. *Clin Orthop Relat Res*. 2005;434(5):251–257.
41. Sanchez-Sotelo J, Munuera L, Madero R. Treatment of fractures of the distal radius with a remodellable bone cement: a prospective, randomised study using Norian SRS. *J Bone Joint Surg Br*. 2000;82(6):856–863.
42. Zimmermann R, Gabl M, Lutz M, Angermann P, Gschwentner M, Pechlaner S. Injectable calcium phosphate bone cement Norian SRS for the treatment of intra-articular compression fractures of the distal radius in osteoporotic women. *Arch Orthop Trauma Surg*. 2003;123(1):22–27.
43. Cassidy C, Jupiter JB, Cohen M, et al. Norian SRS cement compared with conventional fixation in distal radial fractures. A randomized study. *J Bone Joint Surg Am*. 2003;85-A(11):2127–2137.
44. Welkerling H, Raith J, Kastner N, Marschall C, Windhager R. Painful soft-tissue reaction to injectable Norian SRS calcium phosphate cement after curettage of enchondromas. *J Bone Joint Surg Br*. 2003;85(2):238–239.
45. Lu J, Descamps M, Dejou J, et al. The biodegradation mechanism of calcium phosphate biomaterials in bone. *J Biomed Mater Res*. 2002;63(4):408–412.
46. Petruskevicius J, Nielsen S, Kaalund S, Knudsen PR, Overgaard S. No effect of Osteoset, a bone graft substitute, on bone healing in humans: a prospective randomized double-blind study. *Acta Orthop Scand*. 2002;73(5):575–578.
47. Chapman MW, Bucholz R, Cornell C. Treatment of acute fractures with a collagen-calcium phosphate graft material. A randomized clinical trial. *J Bone Joint Surg Am*. 1997;79(4):495–502.



**Orthopedic Research and Reviews****Dovepress****Publish your work in this journal**

Orthopedic Research and Reviews is an international, peer-reviewed, open access journal focusing on the patho-physiology of the musculoskeletal system, trauma, surgery and other corrective interventions to restore mobility and function. Advances in new technologies, materials, techniques and pharmacological agents are particularly welcome. The journal welcomes

original research, clinical studies, reviews & evaluations, expert opinion and commentary, case reports and extended reports. The manuscript management system is completely online and includes a very quick and fair peer-review system, which is all easy to use. Visit <http://www.dovepress.com/testimonials.php> to read real quotes from published authors.

Submit your manuscript here: <http://www.dovepress.com/orthopedic-research-and-reviews-journal>