



Precision Driven Refinement in Orthodontic Anchoring



# Surgical Technique Guide

## **The Orthodontic Mini-Implant (OMI) Surgical Placement Guide**

By

Judah S. Garfinkle, D.M.D. and  
Larry L. Cunningham, Jr., D.D.S., M.D.

### **OMI Indications:**

- OMI's are intended to provide a fixed-point of orthodontic anchorage. They are to be removed after the necessary tooth movement has occurred. In this way, OMI's are to serve as a single-use, temporary anchorage device. OMI's can be loaded immediately after placement, eliminating prolonged latency periods necessary for traditional implant techniques.

### **Site Determination:**

- The optimal location for OMI placement is based on the assessment of both the anatomic limitations and the orthodontic treatment considerations.
- OMI's can be placed anywhere in the maxilla and the mandible in which adequate bone exists, while avoiding surrounding vital structures. Examples of placement locations are the buccal or lingual alveolus, the palate, the maxillary retromola region and the mandibular tuberosity area.

### **Anatomic Considerations:**

- Vital structures (e.g. dental roots, blood vessels, nerves, maxillary sinus, etc.) should be avoided. The use of radiographs and/or other imaging techniques is recommended. Surgical stents can prove helpful as well.
- Attempts should be made to place the OMI through attached gingiva rather than unattached gingiva. This will decrease inflammation, the chance of tissue overgrowth, and simplify the surgical procedure, while increasing the success rate. The thickness of the attached gingiva can be determined prior to placement of the OMI. This will help in choosing the appropriate implant length.

### **Orthodontic Considerations:**

- Since the ultimate goal of an OMI is to provide a point of anchorage against which teeth can be moved, it is paramount to recognize the amount and direction of the desired dental movements prior to placement. Placement of the OMI should be in an appropriate relationship to the orthodontic appliances and readily available to work with the proposed treatment mechanics. For example, if an OMI is placed too apically on the alveolar ridge, it could result in an excessive vertical force vector, interfering with orthodontic sliding mechanics. If an OMI is placed too close to the tooth to be moved, it may be challenging to generate the desired orthodontic biomechanical system.

### **OMI Selection:**

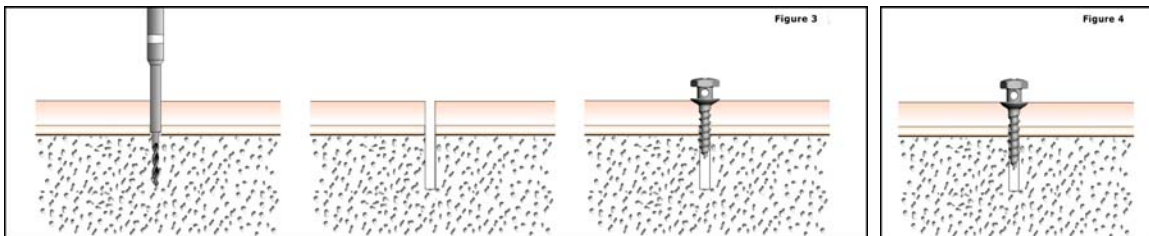
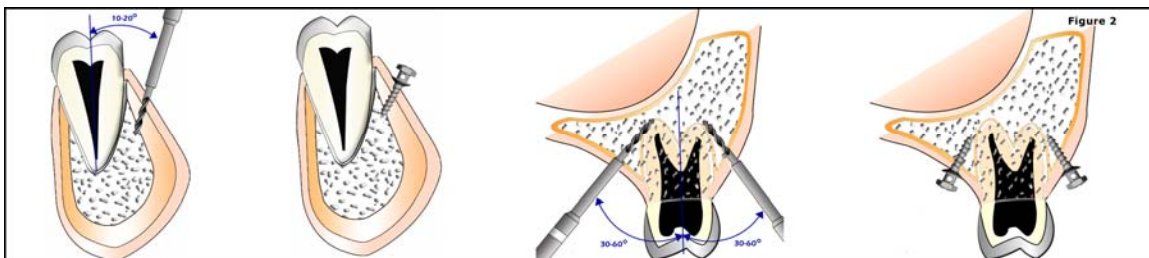
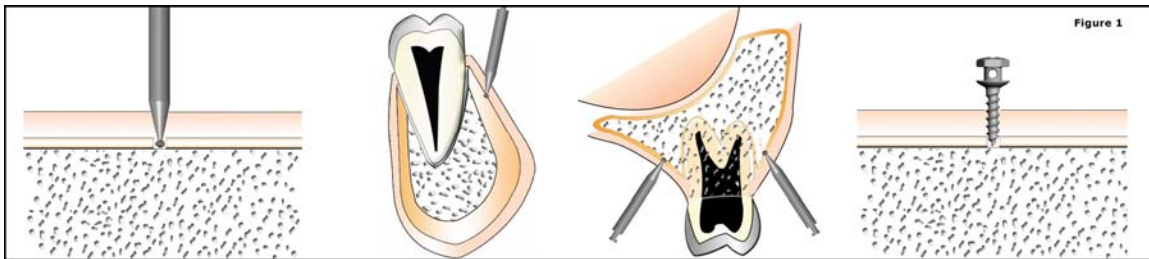
- Length: One of the primary determinants of OMI length is the quantity and quality of the bone at the site of insertion. Since the thickness and density of the mandibular cortex is generally greater than that of the maxilla, the length of the OMI should provide ideally 5mm of mini-implant to bone contact in the mandible and 6mm in the maxilla. For example, if the attached gingiva in the mandible measures 3mm in thickness over the desired insertion point, an 8mm long implant should be selected. The longest OMI should be used that will not compromise the adjacent tissues. The overall length of the OMI will thus depend on the available bone, thickness of the soft tissue and the proximity of vital structures. Diameter: Assuming adequate bone quantity and quality, the 1.2mm diameter OMI should be able to withstand orthodontic forces of approximately 300 grams. When the existing bone is less dense or higher forces are needed, consider using an OMI with a 1.6mm diameter.

### Local Anesthesia:

A small amount of local anesthesia is recommended. Avoiding profound anesthesia of the periodontal ligament will allow the patient to alert the surgeon if the OMI impinges on the root structure.

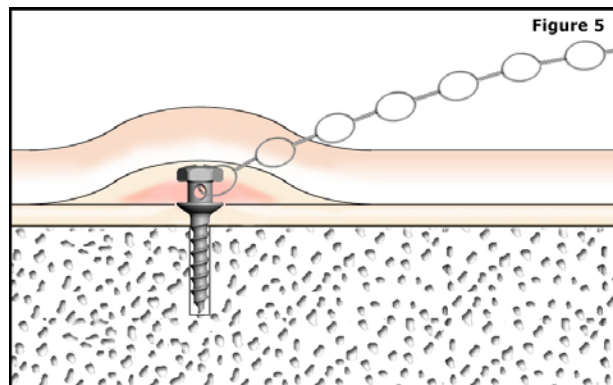
### Placement Into Attached Gingiva (Exposed Technique):

- Confirm adequate anesthesia
- Use a slow-speed drill with a carbide round bur (#2) passing directly through the tissue and 0.5mm into the underlying cortical bone (“cortical notching”). Adequate irrigation should be used. **(fig1)**
- If adequate space exists between the roots of neighboring teeth, the OMI can be inserted perpendicular to the bone. If there are anatomical barriers to consider (e.g. dental roots), the OMI can be placed at an angle to the long axis of the teeth (approximately 30-60°). **(fig2)** The cortical notch provides a sufficient purchase point for an angled path of insertion for the 1.6mm diameter OMI. For the 1.2mm diameter OMI, it is recommended that a pilot hole be extended from the cortical notch through the cortical bone to decrease the chances of OMI fracture during insertion **(fig3)**
- Insert the OMI under manual pressure with the OMI-driver, bringing the bottom of the abutment into contact with the tissue, avoiding severe blanching. **(fig4)**
- Confirm primary stability avoiding rotation of the OMI.
- Orthodontic force can be placed on the OMI immediately. If during insertion the implant cannot be completely seated, it is likely that cementum has been encountered. The implant should be redirected at a new angle or reinserted at a new site if necessary.



**Placement Into Unattached Gingiva (Submerged Technique):**

- The protocol is generally the same as with the Exposed Technique but the OMI should be submerged under the tissue since the incidence of tissue overgrowth/inflammation is much higher in unattached gingiva.
- Placing a stainless steel ligature around the OMI-head resulting in an emerging point of attachment for orthodontic mechanics is preferred in the Submerged Technique. (fig 5)
- Make a small stab incision through the soft tissue at the desired point of insertion. This will eliminate tissue binding around the drill and OMI.
- Use a slow-speed drill with a carbide round bur (#2) to a depth of 0.5mm into cortical bone with adequate irrigation (cortical notching).
- Insert the OMI under manual pressure with the OMI-driver, bringing the bottom of the abutment to the level of the bone. The same issues concerning pilot drilling and the angle of insertion exist as with the Exposed Technique.
- Confirm primary stability avoiding rotation of the OMI.
- Proper suturing of the placement site should be done if necessary, allowing the stainless ligature to pass freely into the oral cavity. If during insertion the implant cannot be completely seated, it is likely that cementum has been encountered. The implant should be redirected at a new angle or reinserted at a new site if necessary.

**OMI Loading/Removal:**

- OMI's can be loaded immediately after placement. Up to 300 grams of orthodontic force can be applied to 1.2mm diameter implants, where as up to 450 grams can be applied to OMI's with a diameter of 1.6mm. These numbers should serve as a guide only. The exact amount of force that an OMI could withstand depends on many factors that need to be considered.
- The orthodontic mechanics are straightforward with the use of nickel-titanium closed-coil springs or elastic-chain. OMI's can also provide indirect anchorage.
- Due to the lack of osseointegration, retrieval of an exposed OMI is easily accomplished with the OMI-driver by unscrewing the implant. This is often done without the need for local anesthesia and healing is uneventful. Retrieval of a submerged OMI requires local anesthesia, exposure of the OMI, and unscrewing of the implant with the OMI-driver. Suturing may be done if necessary; healing is uneventful.

**Cautions/Warnings:**

- Following placement, avoid producing any rotational or torsional forces on the OMI.
- Approaching the height/depth of the vestibule with the OMI abutment may cause tissue impingement and ulceration.
- Avoid placement of the OMI too coronally in the alveolus. Although primary stability may be achieved, the often-thin interseptal bone may lead to premature OMI failure. The roots of the teeth are closer together as well, increasing the chances for root contact.
- If primary stability is not achieved with a 1.2mm diameter OMI, remove the OMI and reinsert a 1.6mm diameter OMI in the same location. If primary stability is not achieved with a 1.6mm diameter OMI, prepare a new placement site and reinsert. Primary stability is absolutely necessary for OMI success.
- Overheating of the supporting bone can result in osteonecrosis, resulting in OMI failure.
- Following insertion, post-operative analgesics are usually not necessary, but once the local anesthesia wears off, a small proportion of patients may complain of dull, aching pain associated with the neighboring teeth. This happens predominately in the mandible and should subside in a couple of days or less. For these patients, prescribing analgesics is appropriate and at the doctors discretion.
- It is recommended that each patient rinse twice a day with a 0.12% Chlorhexidine Gluconate rinse for approximately two weeks or until all signs of inflammation are controlled following surgery. Inflammation of the peri-implant tissues can decrease the success of OMI's, thus diligent oral hygiene practices are necessary for an optimal outcome. Occasional OMI tightening may be necessary. If a slight clockwise turn results in stability, the OMI may remain in place.

**Relative Contraindications:**

- Inadequate bone in quantity or quality.
  - Active oral infection affecting region of insertion.
  - Any mental/neurological conditions that would prohibit the patient from tolerating the placement/retrieval procedure and/or adequately maintaining the necessary oral hygiene of the OMI's.
  - Any condition of immunodeficiency that would interfere with the normal healing process.
- Metabolic conditions affecting bone metabolism.

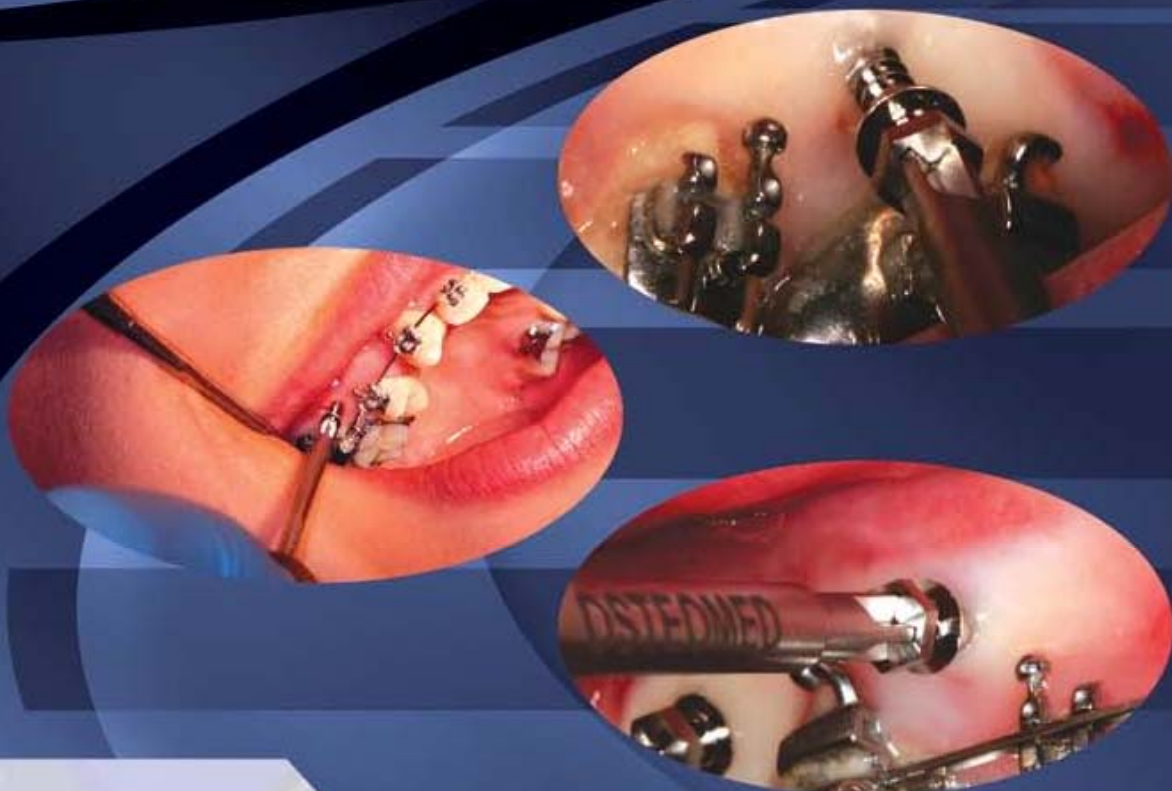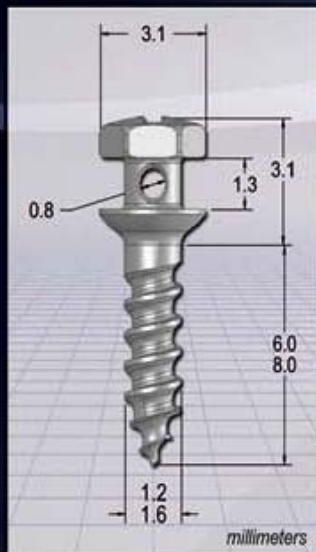
**Bibliography:**

- Costa A, Raffaini M, Melsen B. Miniscrews as orthodontic anchorage: a preliminary report: Int-J-Adult-Orthodon-Orthognath-Surg. 1998; 13(3): 201-9; 1998.
- Kyung HM, Park HS, Bae SM, Sung JH, Kim IB. Development of orthodontic micro-implants for intraoral anchorage. J Clin Orthod 2003;37:321-328; quiz 314.
- Miyawaki S, Koyama I, Inoue M, Mishima K, Sugahara T, Takano-Yamamoto T. Factors associated with the stability of titanium screws placed in the posterior region for orthodontic anchorage. Am J Orthod Dentofacial Orthop 2003;124:373-378.
- Park HS, Kwon TG, Sung JH. Nonextraction treatment with microscrew implants. Angle Orthod 2004;74:539-549.
- Cheng SJ, Tseng IY, Lee JJ, Kok SH. A prospective study of the risk factors associated with failure of mini-implants used for orthodontic anchorage. Int J Oral Maxillofac Implants 2004;19:100-106.
- Fritz U, Ehmer A, Diedrich P. Clinical suitability of titanium microscrews for orthodontic anchorage-preliminary experiences. J Orofac Orthop 2004;65:410-418.



# OMI™

## Orthodontic Anchor System



Photos courtesy of Dr. Judah Garfinkle

## OMI™ Orthodontic Anchor System Catalog Numbers

### Part Number Description

#### Implants

202-1206	1.2mm x 6mm OMI™ Orthodontic Anchor Screw
202-1208	1.2mm x 8mm OMI™ Orthodontic Anchor Screw
202-1606	1.6mm x 6mm OMI™ Orthodontic Anchor Screw
202-1608	1.6mm x 8mm OMI™ Orthodontic Anchor Screw

#### Packaging

202-0001	OMI™ Orthodontic Anchor System Organizer
202-0002	OMI™ Orthodontic Anchor System Tray

#### Screwdrivers

202-0003	OMI™ Orthodontic Anchor Finger Driver
220-0019	Taperlock™ Screwdriver Body

### Part Number Description

#### 1.2mm Instruments

220-0001	1.0mm Pilot Drill, J-Latch
220-0022	1.2mm Screwdriver Shaft, Manual
220-0068	1.2mm Screwdriver Shaft, Dental Latch
220-0165	1.0mm Pilot Drill, 12mm Stop, Dental Latch

#### 1.6mm Instruments

220-0061	1.6mm Screwdriver Shaft, Manual
220-0062	1.3mm Pilot Drill, J-Latch, 16mm
220-0064	1.3mm Pilot Drill, Dental Latch
220-0067	1.6mm Screwdriver Shaft, Dental Latch



[www.osteomedcorp.com](http://www.osteomedcorp.com)

P/N 030-1351